

# TOTAL FACE REJUVENATION

MY FACE LIFT  
METHODOLOGY:  
THE RESULT OF  
20 YEARS OF  
DEVELOPMENT

Dr Frank Muggenthaler

Klinik MUGGENTHALER ÄSTHETIK für  
Plastische Chirurgie und Ästhetische  
Medizin Landstraße 3  
D - 79261 Gutach, Germany  
www.muggenthaler.com

Facial Plastic Surgery Dr. Muggenthaler  
Blumenrain 12  
CH - 4051 Basel, Switzerland  
www.muggenthaler.ch

## INTRODUCTION: MY FOUNDATIONS

Surgeons choose the field of aesthetic surgery (and facial plastic surgery in particular) for different reasons. Each surgeon who has made the choice to dedicate himself/herself to this speciality has acquired, in the course of their journey to perfecting their skill, the experience and explored the various techniques that shape their own unique approach, allowing them to offer their patients the best possible results.

My own personal journey that led to face lift surgery began in my childhood. My father, Dr. Hermann Muggenthaler, had already been practicing as a plastic surgeon in the mid-50s, successfully carrying out all the procedures that were possible, at that time, in this specialist field. He opened one of the first private clinics for aesthetic plastic surgery and was co-founder of the German Society of Aesthetic Plastic Surgery. Always on the lookout for ways in which he could improve the results, he was constantly exchanging ideas with colleagues at home and overseas. I recall vividly the excitement with which my father would talk about his work, having performed a face lift, and even back then I could sense how fascinating it must be to alter a person's face so as to improve their appearance. His enthusiasm for his profession and the importance he attached to his image as a doctor influenced me greatly, while his comprehensive treatment records helped me to master the fundamental groundwork.

Aside from my father, who remains my most important and influential role model to this day, I was impressed by the life and work of Dr. Ivo Pitanguy from an early age. With his dedication to sharing new findings, this outstanding plastic surgeon has filled me with enthusiasm for aesthetic plastic surgery, as he has so many other surgeons.

I was fortunate enough to be able to follow in my father's footsteps, having discovered my special interest for facial surgery early on. I studied dentistry alongside medicine and completed my residency in maxillo-facial and aesthetic plastic surgery. Important focus points of my early work included tumour surgery of the face and neck, as well as orthodontic and craniofacial surgery to correct skeletal misalignment. My subsequent successes in face lift surgery would

not have been possible without these experiences. Tumour surgery requires comprehensive knowledge of the deep anatomical structures of the face and neck, while craniofacial surgery allows for a precise analysis of facial proportions. My training in oral and maxillofacial surgery has provided without a doubt the foundation for my face lifting procedures.

In addition, many years of experience and having performed more than 2,000 face lifts, have allowed me to refine and optimize my techniques in a number of ways. Today, my face lift methodology is characterised by five factors in particular: extensive analysis, the use of an advanced SMAS technique, the optimisation of brow lifting, the optimisation of anaesthesia as well as the application of Obagi's sophisticated skincare concept.

### THE STARTING POINT OF MY WORK: ANALYSIS OF THE FACE AND NECK

Following my training in cranio-maxillo-facial surgery in Germany I was able to gain much insight into the finer points of face lift surgery in the course of a fellowship with Dr. Bruce Connell in Santa Ana, California. This period significantly influenced my professional career and it fills me with pride to be one of Connell's students and to be able to play my part in passing on his extensive knowledge of face lift surgery to younger colleagues. While Pitanguy is indisputably the biggest promoter of aesthetic plastic surgery in the 20<sup>th</sup> century overall, Bruce Connell is regarded by many experienced plastic surgeons as *the* master of face lift surgery – and rightly so, in my opinion. A notable strength of Connell's process is his particularly detailed

method of analysing faces, as well as describing the impression certain anatomical variants convey to the beholder.

He also takes the aging of the face into close consideration. He places great emphasis on the optimisation of the smallest details of his facial surgery procedures. Lastly, the neck area is also given particular attention by Connell. These three distinctive features – the detailed analysis, the fastidious and systematic procedures and the consideration of the neck area – have had a lasting influence on my methodology.

For me, the starting point of a successful procedure is always a thorough analysis of my patient's face. This originated during my fellowship with Bruce Connell. At the time he gave me the task of developing a mechanism to describe the aesthetic appearance of the neck scientifically. The product of my in-depth analysis of this exciting topic is the *Neck Check*. It is often said that the perception of beauty is relative, however many arguments clearly support the idea that beauty is connected to certain prerequisites that are generally applicable. It is particularly important for doctors who practice aesthetic surgery to be aware of these prerequisites and to be able to apply these standards when changing their patient's appearance. The *Neck Check* offers a great opportunity to peruse objective reference points of the neck and to help the surgeon identify the best method in order to obtain the desired treatment outcome.

The actual "window" that connects our soul to the surrounding world is the face, especially the part framed by the eyebrows, cheekbones and chin. This area is also described as the "magic triangle" of the face. The eyes and mouth are most important in that they enable us to express ourselves and obtain information. This is why faces with larger magic triangles appear more expressive than faces with

smaller features. In this context the neck contributes a great deal to the overall aesthetic appearance of the face. The neck should be as inconspicuous as possible in order to draw the observer's attention to the magic triangle. The *Neck Check* I developed takes twenty two criteria into consideration, which describe various proportions of, and anatomical findings in the neck region and converts these into figures. The results of this check form an objective measurement for the aesthetic appearance of the neck. This test is very helpful to me personally and to other surgeons who specialise in face and neck lifting as it enables a precise diagnosis. The necessary treatment steps can therefore be identified with near mathematical precision.

### FURTHER DEVELOPMENT OF THE SMAS TECHNIQUE WITH DEEP FIXATION SUTURES

When I perform a face lift, what is of the utmost importance to me is to restore all of the patient's facial areas to their youthful location and appearance in an even and harmonious manner: the forehead, the eyebrows, the cheeks and last but not least the neck, which is unfortunately often neglected by surgeons during a face lift.

The SMAS face lift has become the standard in face lift procedures over the past years. At this point it is not necessary to outline the fundamental procedures of the SMAS technique, however I would like to touch upon its limitations as well as describe the advances/modifications I have developed that present a number of advantages.

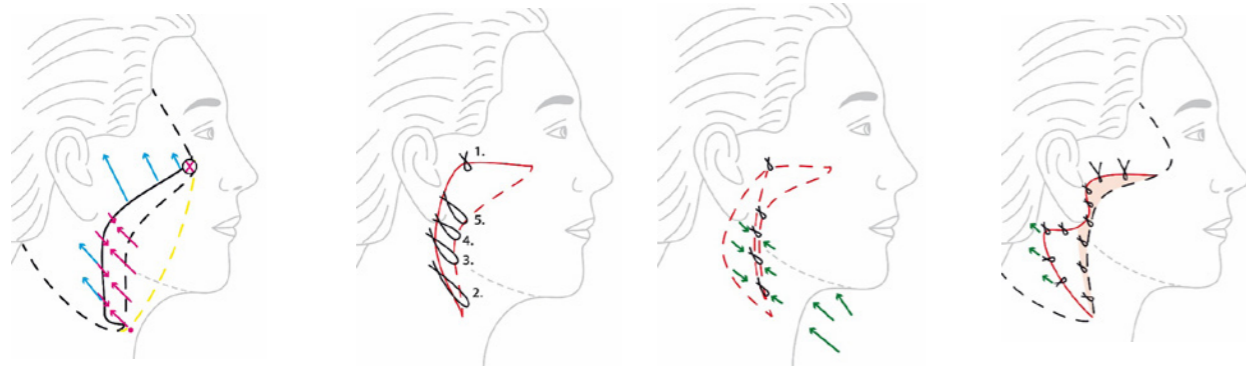
With the classic relocation and suture of the Superficial Musculo Aponeurotic System (SMAS), fixation sutures are merely applied to the flap edges in the cheek area and below the ear. This can

cause the following problems: the expansion of the SMAS/platysma and the tent-shaped tension above the sternocleidomastoid muscle (the muscle on the side of the neck, ED. Drawing) lead to tissue augmentation in those areas and a discreet widening of the neck which can be aesthetically displeasing. This is also why the distinct depression at the front side of this muscle is overlaid by the flaps, which has a negative effect on the clear definition of the jaw angle. Post-operative haemorrhages can also cause problems as they can accumulate to a significant size beneath the mobilised SMAS/platysma flaps, which may require surgical revision.

For many years I have been placing four to five additional 4/0 fixation sutures during my face lifts (non-absorbable, braided polyester thread) which run ventrally from the front edge of the sternocleidomastoid muscle to the underside of the platysma. The advantages: the front edge of the sternocleidomastoid muscle as well as the platysma and subcutaneous fatty tissue attached to it are ventrally relocated, which results in an aesthetically advantageous narrowing of the neck contour. Additionally, the dead space below the platysma and the SMAS is significantly reduced. This also reduces the risk of a post-operative haemorrhage necessitating a revision. The additional fixation sutures allow for an even better tightening of the platysma and for an optimal contouring of the neck profile than with the usual SMAS technique. My method also facilitates a comparatively easy method of lifting sunken and enlarged submandibular glands (the glands below the chin, ED Drawing).

On one hand this procedure enables me to achieve an optimal shaping of the face, especially the contour of the cheeks and neck. On the other hand the risk of complications which occur more frequently with other face lift methods is reduced to an absolute minimum. Thanks to this method





**Image 1:** Depiction of the expansion of the skin dissection (dark dotted line), the expansion of the SMAS/platysma preparation (yellow dotted line), the stress vectors following the deep suspension sutures (red arrows) and the relocation of the SMAS to the cranial and posterior (blue arrows).

**Images 2 and 3:** Sequence of fixation sutures: the first suture elevates the SMAS to the approximate level of the zygoma (cheekbone). The following sutures put the platysma under tension and reduce the dead space under SMAS and platysma successively.

**Image 4:** The overlap of the SMAS/platysma flap is then turned under the ear and similarly fixed.

I can substantially spare my patients from these complications, which specifically include post-operative haemorrhaging, nerve damage or pain. Following this procedure, my patients experience significantly fewer issues with swelling and discolouration than patients who were operated on using other face lift methods. Finally, this protective procedure also means that I can carry out every face lift using twilight anaesthesia (see below).

### OPTIMISATION OF BROW LIFTING THROUGH MODIFIED SUBCUTANEOUS BROW LIFTING

Wide, large, bright eyes are a central aim for all surgical procedures intended to give the face a younger, more harmonious appearance. Lid correction is a correspondingly important factor in aesthetic facial surgery. The impression of a tired appearance is caused not least by the age-related sinking of the eyebrows. The sinking of the forehead and a low brow position can lead to an apparent excess of skin on the upper eyelids, a so-called pseudoblepharochalasis. If this is ignored during the planning of the treatment, the improvement of the appearance is incomplete or

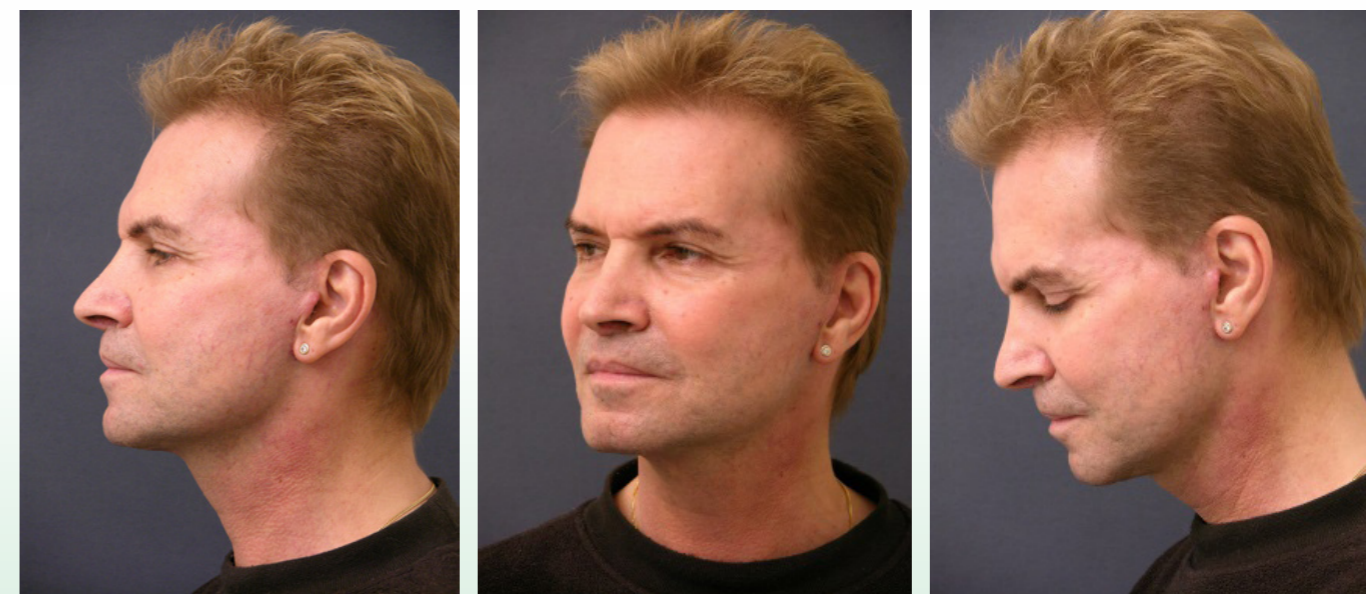can even lead to a reduction of the periorbital area. My solution for good results in the brow region is a limited subcutaneous brow lifting which can be adapted to individual needs, is relatively easy to carry out, and very effective.

In medical literature, endoscopic techniques of the sub-periosteal brow lifting are seen as the “gold standard” for the lifting of the eyebrows, pretending that visible scars may be avoided by this approach. However, the subperiosteal procedure is anything but sparing and can lead to significant and long lasting oedema and paraesthesia. In my opinion, one crucial disadvantage of endoscopic brow lifting is its insufficient effectiveness, as it merely leads to a slight lift of the brows and does not offer sufficient long-term effects. Good long-lasting results are only achieved by a few very experienced doctors, while the indication for this technique appears to be limited to younger patients with no significant excess skin in the brow area. In these cases in particular a simple botulinum toxin treatment of the lateral orbicularis oculi muscle can achieve a similar or even more satisfying lift of the brows.

The subcutaneous brow lift with the incision at the hairline receives little attention in

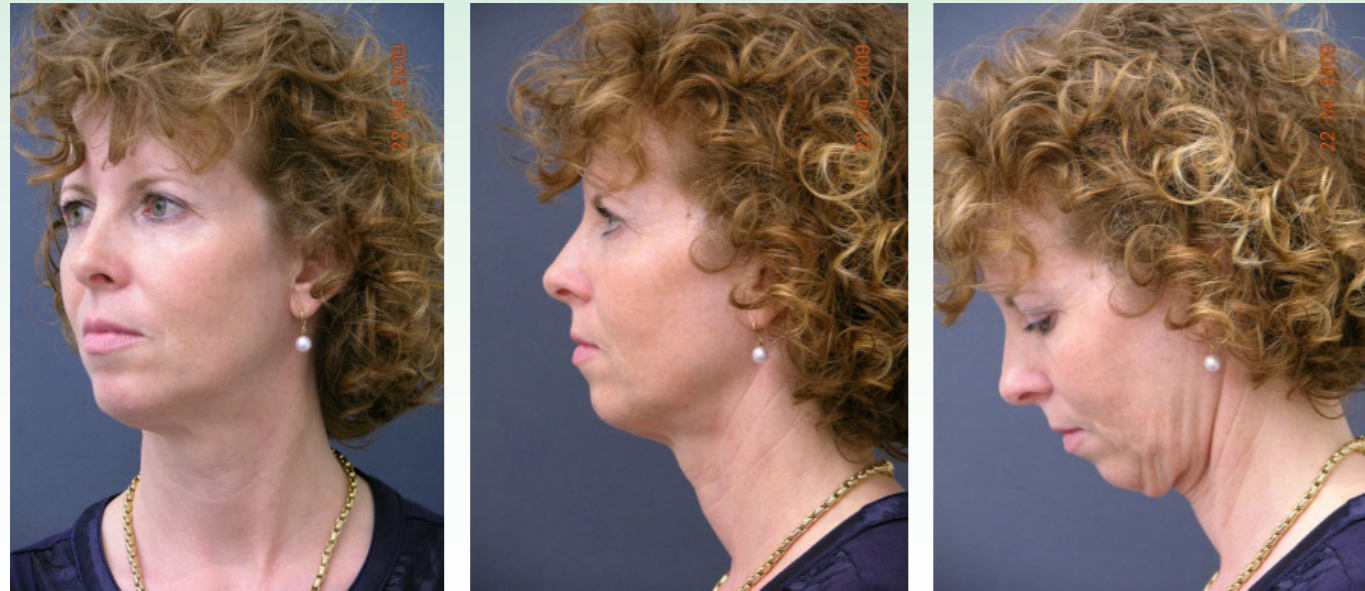

**Images of patient 1 before the operation:**  
60 year old patient with elastosis and rhytidosis of the cheeks and neck.



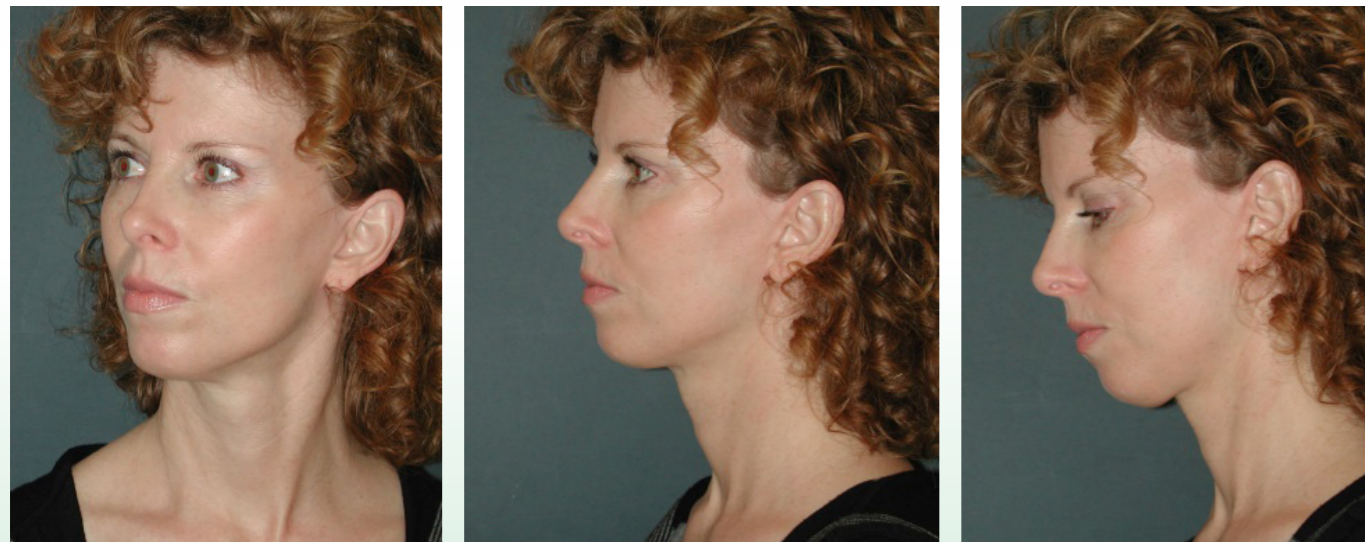**Images of patient 1 after the face lift:**  
The same patient after a face and neck lift with the implementation of deep suspension sutures and submandibular liposuction.





**Images of patient 2 before the operation:**

44 year old patient with significant cervico-facial elastosis as well as low positioning of the enlarged submandibular glands.



**Images of patient 2 after the face lift:**

The same patient after face and necklift with the application of subplatysmal fixation sutures.

literature, despite being the oldest procedure with verifiably impressive and long-lasting brow lifting results. Reservations towards this technique are presumably based on two fundamental factors: firstly with the dissection of the forehead skin over a large area, circulatory disorders can occur more easily at the edges of the skin flaps, in particular in the upper temporal region, than with other well-known techniques. Secondly, unsightly and obvious scarring can occur when the incision is consequently carried out along the entire hairline, as the hair shafts generally run at a sharp dorsal angle in the upper temporal area and therefore do not obscure the scars.

In order to minimise the risks mentioned I apply the subcutaneous brow lift in a modified form, using two separate horizontal incisions, lateral to the midline with a length of 4 to 5 cm each. With a careful and protective method of incision and dissection the advantages of the technique are obvious: it is an easy and timesaving procedure which allows a very effective repositioning of the brows, while the individual extent of the brow lift can easily be adapted. Furthermore this procedure does not cause any permanent loss of skin sensitivity and leads to very good long lasting results. I either carry out the subcutaneous brow lift in combination with a total face lift or as an isolated procedure in order to correct pseudoblepharochalasis. In many cases this eliminates the need to carry out blepharoplasty of the upper eyelids.

### OPTIMISATION OF THE ANAESTHETIC PROCEDURE

Anaesthesia is an important component of my face lift method. Unlike the majority of my colleagues I carry out almost all of my face lifts using so-called twilight anaesthesia. Over the years I have

refined this technique. The most important aims of applying twilight anaesthesia are controlling the patient's circulation and blood pressure, avoiding pain and improving the overall wellbeing of my patients. Last but not least, this technique also enables better surgical results.

In order to keep my patient's circulation stable on the day of the face lift and post-op, I apply a well-balanced premedication. I use a highly effective and safe combination of sedatives, long lasting pain killers and medication to reduce swelling. If required, liquids and medication can be admitted via infusion during the procedure. The patient's circulation and cardiac function are continuously monitored, while local anaesthesia ensures complete absence of pain. My knowledge of the facial anatomy and facial nerves allows me to administer the anaesthetic exactly and effectively.

In my clinic we make sure that our patients feel comfortable and safe during the surgery as well, which is supported by the gentle twilight anaesthesia. Additionally we provide a calm and relaxing environment: warm blankets, a comfortable operating table cover and relaxing music to create a pleasant atmosphere. The success of an operation does not depend on the surgical procedure alone, however. The immediate recovery period is also very important for a successful outcome. The twilight method enables our patients to experience a much faster recovery period and a far more pleasant surgical procedure, including the hours following the procedure. Avoiding general anaesthesia is better for the circulatory system, which in turn benefits the healing and recovery process. Twilight anaesthesia patients are able to socialise again at a significantly quicker pace than following a face lift under general anaesthesia.

A face lift with twilight anaesthesia is not just a safer and more pleasant method for the patient, it





Image of modified and limited brow lift technique: horizontal incision at hairline, area of subcutaneous skin dissection, skin elevation with buried absorbable fixation sutures.

also facilitates a better monitoring of results. This technique allows me to discern and reproduce the patient's facial expression very well during surgery, unlike with general anaesthesia. Nerve damage is also more easily avoided than with the conventional method.

## INTEGRATION OF OBAZI'S SKINCARE CONCEPT

For me the integration of a highly efficient skin care is a crucial requirement for the success of aesthetic surgical procedures. The recognition that a complete rejuvenation of the face is only possible with due consideration to the skin quality has had a significant influence upon my face lift method. It is one thing to restore younger, more harmonious facial proportions with a face lift, but for a face to truly look younger, fresher and healthier the skin's signs of aging need to be corrected and neutralised as well. In accordance with this knowledge I have been regularly exchanging ideas with dermatologists for many years and have as a result integrated many valuable ideas from there into my work as a surgeon.

The desire to have beautiful skin is probably one of the most important attributes of human culture. All known aids, remedies, balms and

techniques have been in existence for a very long time and the choice of products on the cosmetic market is predictably vast. Unfortunately, the majority of well-known cosmetic products only achieve very limited results. If, however, one is aware of the exact mechanisms of skin aging and of the substances that have an effective correcting effect on the skin, one can achieve astonishing corrections to the aging skin and an overall improvement in skin quality. In this respect we owe much to the Californian dermatologist Dr. Zein Obagi, who developed systematic treatment methods for the skin as early as the 1980s. It is based upon a five step programme, through which practically any type of skin can regain its healthy, beautiful qualities. The steps recommended by Obagi include cleansing, activation, stimulation, calming and care, as well as protection.

With a systematic skin treatment concept such as Obagi's the problems of aging skin can be solved where they originate, thanks to a targeted and attuned use of effective cleansing, antioxidants, bleaching agents, vitamin A or retinoids. I recommend this treatment to all of my patients. Adopting a good skin regimen is critical in order to improve the appearance and quality of the skin and to achieve complete rejuvenation, especially before and after a face lift procedure.

## SUMMARY

In the past, face lifts were primarily requested and offered as individual procedures. Today, aesthetic facial surgeons should place emphasis on the complete and harmonic rejuvenation of the . On my journey to develop my own face lift methodology I have taken much inspiration from many excellent teachers. I have practised and optimised the essential key techniques for successful face lift surgery. The classic SMAS lifting is the solid basic approach, similar to the frame of a car, on which my procedure relies. Thorough analysis is the starting point that makes the aim of my work discernible and makes its results measurable.

My adaptation of the SMAS method, using deep fixation sutures, and the modified subcutaneous brow lift have allowed me to achieve optimal contouring – not least of those facial areas that significantly contribute to a youthful appearance and radiance. The consistent application of twilight anaesthesia helps me monitor the results and makes the procedure as pleasant and safe as possible for the patient. The integration of a carefully balanced skincare concept rounds off the results of my work perfectly.

Using a combination of various complementary procedures, surgical modifications and supporting measures I can promise my patients exactly what they want in good faith: total facial rejuvenation.

### REFERENCES:

- Baker C. Daniel: Face Lift With Submandibular Gland and Digastric Muscle Resection: Radical Neck Rhytidectomy, *Aesth Surgery J.* 26:85, 2006
- Bernard R W, Greenwald, J A, Beran, S J, Morello D C: Enhancing Upper Lid Aesthetics with the Lateral Subcutaneous Brow Lift. *Aesthetic Surgery Journal*, 2006, Volume 26, Seiten 19 - 23
- Bruce V, Young A (1998) In the eye of the beholder, the science of face perception. Oxford university press, p 139
- Connell BF: Facial rejuvenation. In Brent B (ed): *The Artistry of Reconstructive Surgery*. St Louis, CV Mosby, 1987
- Connell BF: Neck contour deformities: Ther art, engineering, anatomic diagnosis, architectural planning and aesthetics of surgical correction. *Clin Plast Surg* 14:4, 1987
- Connell B F, Lambros Val S: The Forehead Lift: techniques to avoid complications and produce optimal results. *Aesthetic Plast Surg*; 1989, Volume 13, Seiten 217 - 237
- Connell BF, Marten TJ: Deep layer techniques in cervico-facial rejuvenation. In Psillakis J (ed): *Deep Face lifting Techniques*. New York, Thieme Medical Publishers, 1994
- Connell BF, Marten TJ: Face lift. In Cohen M (ed): *Mastery of Plastic and Reconstructive Surgery*. Boston, Little Brown, 1994, pp 1873-1902
- Ellenbogen R, Karlin JV: Visual criteria for success in restoring the youthful neck. *Plast Reconstr Surg* 66:826, 1980
- Giampapa Vincent: Long-Term Results of Suture Suspension Platysmaplasty for Neck Rejuvenation: A 13-Year Follow-up Evaluation. *Aesthetic Plastic Surgery (Springer)*, 29:332, 2005
- Guyuron B, Davies B: Subcutaneous anterior hairline forehead rhytidectomy. *Aesthetic Plast Surg*, 1988; Volume 12, Seiten 77 - 83
- Knize D M: Limited Incision Forehead Lift for Eyebrow elevation to enhance upper blepharoplasty. *Plast Reconstr Surg* 2000, Volume 105, Seiten 1120 - 1127
- Marten J. Timothy: Face lift: Planning and Technique, *Clin Plast Surg*, April 1997
- Marten J. Timothy: Maintenance Face lift: Early Face lift for the younger Patient, Course #802, The Aesthetic Meeting, New Orleans, 2005
- Mitz V, Peyronie M: The superficial musculoaponeurotic system (SMAS) in the parotid and cheek area. *Plast Reconstr Surg* 58:80, 1976
- Miller T A: Lateral Subcutaneous Browlift. *Aesthetic Surgery Journal*, 2003, Volume 23, Seiten 205 - 210
- Muggenthaler F: der Neck Check - ein neues Analyseverfahren zur Bestimmung der Halsästhetik. *FACE - international magazine of orofacial esthetics*, 4/2007, 26 - 33
- Muggenthaler F: Das umfassende Gesichtslifting. *Der MKG - Chirurg*. Issue 3, November 2008, 176 - 180
- Randall P, Skiles MS: The "SMAS sling"; An additional fixation in face lift surgery. *Ann Plast Surg* 12:1, 1984
- Singer P. David, Sullivan K. Patrick: Submandibular Gland I: An Anatomic Evaluation and Surgical Approach to Submandibular Gland Resection for Facial Rejuvenation. *Plast Reconstr Surg* 112:1150, 2003
- Skoog T: Useful Techniques in Face Lifting. Presented at the Annual Meeting of the American Association of Plastic and Reconstructive Surgeons, San Francisco, 1969
- Stuzin JM, Baker TJ, Gordon HL: The relationship of the superficial and deep facial fascias: Relevance to rhytidectomy and aging. *Plast Reconstr Surg* 89:3
- Sullivan K. Patrick: Contouring the Aging Neck With Submandibular Gland Suspension. *Aesthetic Surgery J.* 26:465, 2006
- Troilius C A: A Comparison between subgaleal and subperiosteal brow lifts. *Plast Reconstr Surg*, 1999, Volume 104, Seiten 1079 - 1090